



Post-traumatic gangrenous acalculous cholecystitis: A case report

Peter Runodada¹, Chenesa Mbanje¹, Aspect J.V. Maunganidze¹, Simbarashe G. Mungazi*²

¹Department of Surgery, College of Health Sciences, University of Zimbabwe, Harare, Zimbabwe

²Department of Surgery and Anaesthetics, National University of Science and Technology, Bulawayo, Zimbabwe

*Correspondence: sgmungazi@gmail.com

<https://dx.doi.org/10.4314/ecaajs.v22i3.9>

Abstract

Acute acalculous cholecystitis in trauma patients is an elusive diagnosis, more so if the patient sustained blunt abdominal trauma. It can arise as a post-traumatic or postsurgical complication, occurring more in critically ill patients. A high index of suspicion for acalculous cholecystitis must be maintained for critically ill patients with newly developing symptoms or septicemia.

We describe a case of a 27-year-old male patient who sustained blunt abdominal trauma in a road traffic accident. He had at least grade III liver injury and later developed gangrenous acalculous cholecystitis, which was confirmed histopathologically after open cholecystectomy.

Keywords: gangrenous acalculous cholecystitis, trauma, cholecystectomy

Introduction

Inflammation of the gallbladder without evidence of calculi or sludge comprises 2% to 15% of all cases of acute cholecystitis and is termed acalculous cholecystitis.¹ Acute acalculous cholecystitis (AAC) is known to occur in critically ill patients following cardiac surgery, abdominal vascular surgery, severe trauma, burns, prolonged fasting, total parenteral nutrition, or sepsis, and is believed to have a worse prognosis as compared with acute cholecystitis associated with stones.² It has been speculated that in such situations, there is no stimulus for the gallbladder to contract, the bile becomes inspissated, and biliary sludge forms.^{2,3} A high index of suspicion is warranted because the presentation of AAC is masked by the underlying condition or the patient might be on mechanical ventilation. We present a 27-year-old male patient with gangrenous acalculous cholecystitis following blunt abdominal trauma with grade III liver injury.

Case presentation

A 27-year-old gentleman was involved in a road traffic accident (RTA) and temporarily lost consciousness before being taken to the nearest hospital and immediately resuscitated. He was transferred to Parirenyatwa Group of Hospitals (PGH) 14 hours later. The patient was managed according to the Advanced Trauma Life Support (ATLS) protocol. He had abdominal pain, band-like in nature and generalised but more marked on right upper quadrant, with no associated vomiting. The patient also had right-sided chest pain, which was stabbing in nature and aggravated by coughing, with no associated shortness of breath or wheezing. He had a frontal headache with no blurred vision or photophobia. Other systems were normal.

On examination, the patient was stable and alert, pink with no jaundice. His pulse rate ranged from 120 to 141 bpm. His respiratory rate was 20 breaths/minute and his blood pressure was

89/45 mmHg. The patient had only received 1 L of normal saline before transfer to PGH. We resuscitated the patient with Ringer's lactate solution and the pulse came down to 105 bpm, with a blood pressure ranging between 128/78 and 135/84 mmHg. The chest examination was unremarkable with equal air entry, normal heart sounds, and no murmurs. The abdomen was symmetrically full, with right upper quadrant bruises; it was soft, with generalised mild tenderness but no guarding. There was shifting dullness and scanty bowel sounds. On digital rectal examination, there was no blood on the glove and normal sphincter tone. Other systems were normal, and we made a diagnosis of blunt abdominal trauma with probable solid organ (liver) injury.

The patient was put on intravenous fluids, oxygen by face mask, narcotic analgesia, and he was catheterised. A focused assessment with sonography for trauma (FAST) was done and showed fluid in Morrison's pouch and paracolic gutters. The initial haematological investigations showed a leukocytosis of $23.4 \times 10^3/\text{mm}^3$ (reference: 4 to $11 \times 10^3/\text{mm}^3$), a haemoglobin of 11.7 g/dL (reference: 14 to 17 g/dL), and normal urea and electrolytes. The patient had elevated transaminases, with aspartate aminotransferase (AST) of 1270 U/L (reference: 0 to 35 U/L) and alanine aminotransferase (ALT) of 1085 U/L (reference: 3 to 36 U/L), with a normal alkaline phosphatase and albumin. A formal ultrasound scan (USS), conducted by a radiologist, showed fluid in Morrison's pouch and a heterogeneous liver, suggesting liver injury. A computed tomography (CT) scan of the abdomen showed subcapsular haematoma and parenchymal liver injury on the right lobe of at least grade III (Figure 1). The spleen had a homogeneous appearance, and the kidneys were normal. There was free fluid in the abdomen, with more in the right upper quadrant.

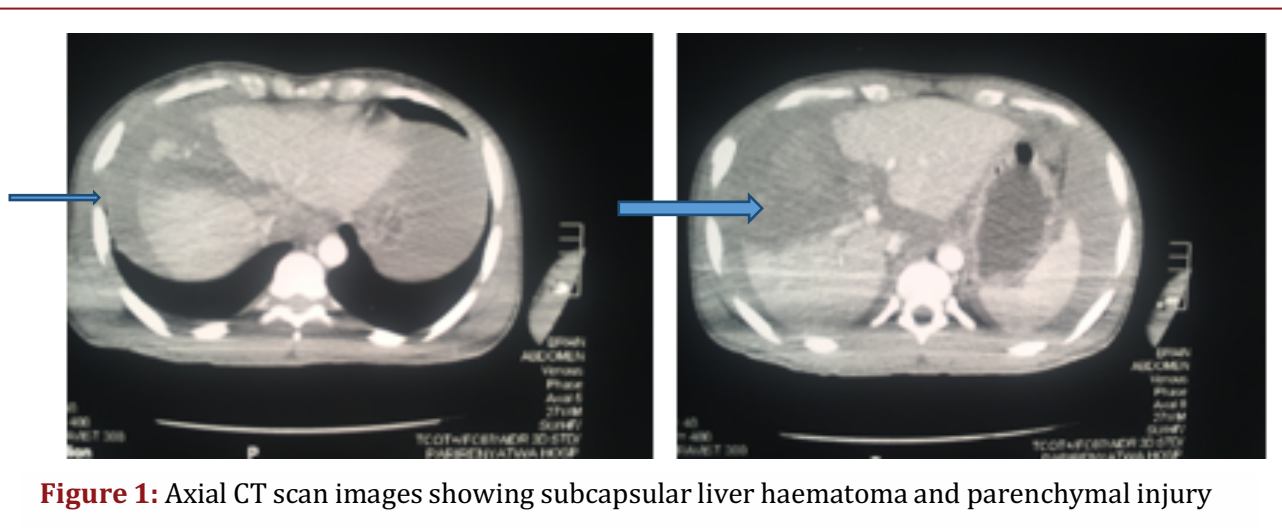


Figure 1: Axial CT scan images showing subcapsular liver haematoma and parenchymal injury

The patient was admitted to the high care unit and conservative management was instituted with close follow-up and serial examinations. On post-admission day 1, the patient was haemodynamically stable with a pulse of 97 bpm and a blood pressure range of 115-132/68-75 mmHg. He was afebrile, and the abdomen was soft, with mild tenderness on the right upper quadrant and scanty bowel sounds. On day 3 post-admission, he was mobilising. He had a white cell count of $11.7 \times 10^3/\text{mm}^3$ and haemoglobin of 9.7 g/dL. On post-admission day 4, the patient experienced a sudden deterioration, was in respiratory distress with a respiratory rate of 26 breaths/minute and alar flaring, and a tachycardia of 122 bpm, although normotensive. The

patient had a low-grade pyrexia of 37.5°C; the abdomen was full and displayed guarding with marked tenderness on right upper quadrant and absent bowel sounds. The patient was continued on intravenous fluids and antibiotics, oxygen by face mask, and prepared for emergency exploratory laparotomy.

Intraoperatively, 4-quadrant packing was done with abdominal swabs. Four litres of altered blood was suctioned and there was no active bleeding noted on exploration of the abdomen. However, a 2 cm deep liver laceration was noted, which was not bleeding, along with a gangrenous gallbladder (Figure 2). Open cholecystectomy was performed, a drain was left in situ on the liver bed, and the patient was not extubated and admitted to the intensive care unit (ICU).

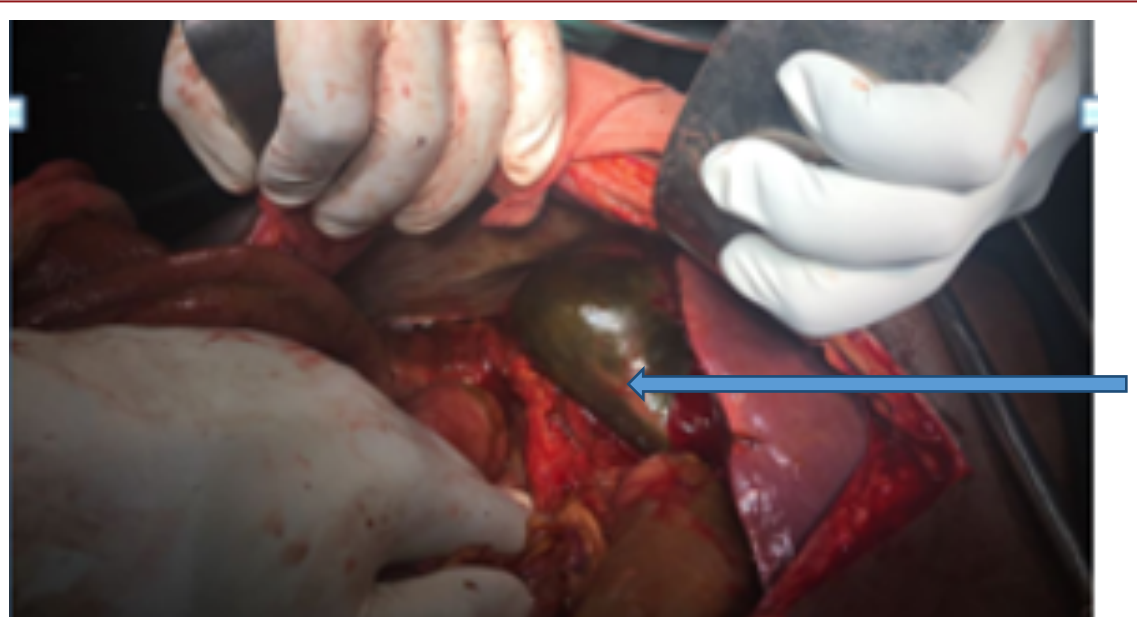


Figure 2: Intraoperative view of gangrenous gallbladder

Postoperatively, the patient stayed in the ICU for 2 days, and his recovery was uneventful. He was discharged from hospital on postoperative day 4. Histology confirmed haemorrhagic necrosis of the gallbladder with inflammatory infiltrates, congested blood vessels, and intramural thrombi, with no evidence of malignancy. The patient was reviewed as an outpatient 2 weeks after discharge, and he was doing well.

Discussion

The exact pathogenesis of AAC is unknown but likely involves some combination of ischaemia, biliary stasis, and sepsis. Inspissated bile and sludge also seem to play some causative role.⁴ A male predominance is seen in cases of acalculous cholecystitis, in contrast to acute calculous cholecystitis, which occurs most often in women.⁵ Acute cholecystitis associated with gallbladder stones is a common and well-known disease. Diagnostic criteria for this kind of acute cholecystitis are clearly defined and the management is mostly routine. The situation for post-traumatic AAC is not as clear, and it is a disease with a reported mortality rate of up to 75%.⁶



A prospective study evaluating trauma patients with serial USS examinations found that the incidence of acalculous cholecystitis in severely injured patients (injury severity score ≥ 12 , requiring intensive care for > 4 days) was 11%, which is similar to other reports.⁴ In addition, 3 factors were correlated with an increased risk of developing acalculous cholecystitis in this high-risk population: (1) high injury severity score, (2) increased heart rate, and (3) transfusion requirement at the time of admission.¹ The study suggests that more acutely injured patients, who are expected to require prolonged ventilatory and nutritional support, are at higher risk for the development of acalculous cholecystitis.¹

Risk factors for the development of AAC have been studied but are still not clearly understood. Shock, blood transfusion requirement, activation of factor XII, duration of ventilatory support, positive end-expiratory pressure, opioid therapy, parenteral nutrition, hyperalimentation, and biliary stasis have been shown to be risk factors for the development of AAC.^{5,7-9} With the difficulty in diagnosis and its fulminant course, AAC is frequently associated with empyema, gangrene and perforation, as well as significant morbidity and mortality.⁹ Patients with these risk factors, injury severity score > 12 , heart rate at admission to the ICU > 100 bpm, and > 4 units of packed red blood cells required before admission to the ICU can often be expected to require prolonged analgesic sedation, nutritional support, and ventilatory support, all of which are found to be risk factors for development of acalculous cholecystitis.^{2,3}

AAC tends to occur in critically ill patients. Its diagnosis is difficult and needs a higher index of suspicion to avoid its deleterious consequences. Although there are several significant differences between patients who develop AAC and patients who do not (tachycardia, pH at admission to the ICU, number of units of packed red cells required before admission to the ICU, ventilatory support and analgesic sedation, nutritional support), it should be kept in mind that trauma severity is the only risk factor that is an independent variable.^{2,7,8} All other risk factors are associated with trauma severity and are therefore dependent variables.² Our patient had a grade III liver injury, which gives an injury severity score (ISS) of 25, though he was haemodynamically stable until day 4. The patient did not have the typical signs for acute gallstone cholecystitis, and as such, the diagnosis was confirmed intraoperatively and on histology.

The initial CT scan and USS did not show any features of acute cholecystitis. This might be due to early acquisition of CT scan and USS, which were taken on the same day of injury. Due to financial constraints, the patient could not afford repeat or serial CT scan or USS, hence serial clinical examination was instituted. The incidence of gangrene and perforation seems to be increased in patients with acalculous cholecystitis compared with acute calculous cholecystitis, likely because of the delay in diagnosis that is common with this disease. In many series, the risk of severe gallbladder complications was found to be 50% to 60%.^{1,2} This high risk may be the result of the disturbance in capillary microcirculation that has been shown in pathologic studies on gallbladder specimens after cholecystectomy for acalculous cholecystitis.¹

Our patient was noted to have gangrenous acalculous cholecystitis intraoperatively and on histology of the specimen. The initial imaging test is usually USS, which classically reveals gallbladder distension, a thickened gallbladder wall, and biliary sludge without stones.⁴⁻⁶ USS is widely available and easy to use, even in acutely ill patients, because it can be performed at the bedside, and it is inexpensive.^{3,10} USS should be performed as the initial imaging modality for suspected acalculous cholecystitis. Evaluating the natural history of abnormalities visualised on



USS in acutely injured patients is problematic. In this case, the patient had a USS on presentation, which only showed fluid in Morrison's pouch, with a heterogeneous liver. The gallbladder was noted to be normal. With an equivocal diagnosis, a CT scan has been shown to be valuable in acalculous cholecystitis and can also help in ruling out other pathologies.⁹

When a patient's diagnosis is questionable based on physical findings or US evaluation or both, hepatobiliary scintigraphy may be used but was not used on this patient.²

The definitive treatment for acalculous cholecystitis is cholecystectomy, which can be performed laparoscopically in most cases. In patients who are critically ill, placement of a percutaneous cholecystostomy tube allows for decompression of the gallbladder and drainage of contaminated, infected bile, and this allows time for the patient to recover from the acute illness before considering proceeding with cholecystectomy.⁴⁻⁶ In this case, the patient underwent open cholecystectomy and recovery was uneventful.

Conclusions

Acute cholecystitis is easily recognised in most patients. However, the presence of acute cholecystitis complicating trauma is much less obvious. Lack of clinical and biochemical specificity in the presentation contributes to delays in diagnosis and treatment. The high incidence of necrosis, gangrene, and perforation in acute cholecystitis complicating trauma dictates the need for immediate surgical intervention. The choice of operation depends on local anatomy, pathology, and the general condition of the patient. Patients with severe injury who are tachycardic and have required several units of blood at admission to the ICU should be monitored early.² Particular attention should be devoted to ultrasound and major clinical symptoms. When a highly pathologic ultrasound is found in combination with major clinical symptoms, cholecystectomy should be performed. Daily laboratory data are of no additional value regarding the decision to perform cholecystectomy.

Acknowledgements

I would like to acknowledge Professor G.I. Muguti for his guidance, wisdom, and mentorship, and I also thank the Department of Pathology at Parirenyatwa Group of Hospitals for the pathological report.

References

1. Okada Y. Posttraumatic acute cholecystitis. *Am J Forensic Med Pathol.* 1987;8(2):164-168.
2. Pelinka LE, Schmidhammer R, Hamid L, Mauritz W, Redl H. Acute acalculous cholecystitis after trauma: a prospective study. *J Trauma.* 2003;55(2):323-329. doi:10.1097/01.TA.0000054648.26933.21.
3. Buckley PM, Hunter JM. Acute acalculous cholecystitis following multiple skeletal trauma. A report of three cases. *Anesthesia.* 1985;40:23-26.
4. Hamp T, Fridrich P, Mauritz W, Hamid L, Pelinka LE. Cholecystitis after trauma. *J Trauma.* 2009;66:400-406. doi:10.1097/TA.0b013e31815ede1.
5. Howard RJ, Delaney JP. Posttraumatic cholecystitis. *JAMA.* 1971;218(7):1006-7.



6. Ganpathi IS, Diddapur RK, Eugene H. Acute acalculous cholecystitis: challenging the myths. *HPB*. 2007;9:131-134. doi:10.1080/13651820701315307.
7. Johnson LB. The importance of early diagnosis of acute acalculous cholecystitis. *Surg Gynecol Obstet*. 1987;164:197-203.
8. Herlin P, Ericsson M, Holmin T. Acute acalculous cholecystitis following trauma. *Br J Surg*. 1982;69:475-476.
9. Dupriest RW, Khaneja SC, Cowley RA. Acute cholecystitis complicating trauma. *Ann Surg*. 1979;189(1):84-89.
10. Cornwell EE 3rd, Rodriguez A, Mirvis SE, Shorr RM. Acute acalculous cholecystitis in critically injured patients. *Ann Surg*. 1989;210(1):52-55.